J Gastroenterol
DOI 10.1007/s00535-017-1403-5

The Japanese Society of Gastroenterology

ORIGINAL ARTICLE—ALIMENTARY TRACT

Endoscopic diagnosis of hiatus hernia under deep inspiration is not consistent with esophageal manometric diagnosis

Yuriko Hanada[1] · Shintaro Hoshino[1] · Yoshimasa Hoshikawa[1] · Nana Takenouchi[1] · Mariko Umezawa[1] · Noriyuki Kawami[1] · Katsuhiko Iwakiri[1]

Received: 3 August 2017 / Accepted: 16 October 2017

Abstract
Background To investigate the relationship between endoscopic and esophageal manometric hiatus hernia (HH).
Methods Forty-six gastroesophageal reflux disease patients with endoscopic HH under maintenance therapy were recruited. Endoscopy was performed on all patients in a fully conscious state. Endoscopic HH was defined as apparent separation greater than 1 cm of the lower margin of the esophageal palisade vessels and the diaphragm hiatus on endoscopy under deep inspiration. Esophageal manometry was conducted using high-resolution manometry (HRM). The length between the lower margin of the lower esophageal sphincter and pulmonary inversion point was measured 10 times. The mean and maximum of the length was then calculated.
Results The mean HH length on HRM was 0 cm (0–0) [median (25th to 75th percentile)], 0 cm (0-0), 0.5 cm (0–1.1), and 2.2 cm (1.3–2.5) in the groups with endoscopic HH lengths of 1–2, 2–3, 3–4, and 4–5 cm, respectively. The maximum HH length on HRM was 0 cm (0–0), 0 cm (0–0), 0.8 cm (0–1.4), and 2.4 cm (1.5–2.9) in the 1–2, 2–3, 3–4, and 4–5 cm endoscopic HH groups, respectively. The mean and maximum HH lengths increased significantly in the group with an endoscopic HH length of 4–5 cm compared with the other groups, but did not differ significantly among the 1–2, 2–3, and 3–4 cm groups. Of patients with endoscopic HH less than 3 cm, few had esophageal manometric HH greater than 2 cm.
Conclusions Endoscopic diagnosis of HH under deep inspiration is not consistent with esophageal manometric diagnosis, leading to overdiagnosis.

Keywords Hiatus hernia · Esophageal high-resolution manometry · Endoscopy

Introduction

In a study that evaluated etiological factors of reflux esophagitis by multivariate analysis [1–3], esophageal hiatus hernia (HH) was reported to be one such factor. Regarding the relationship between HH diagnosed by esophagography and reflux esophagitis, delayed esophageal acid clearance, prolonged esophageal acid exposure, and severe reflux esophagitis were observed according to the increase in the HH hernia length [4].

As the esophageal acid exposure time is judged to be abnormal when it was 4.2% or higher within a 24-hour period [5], patients in whom the esophageal acid exposure time is 4.2% or higher are considered more likely to develop esophageal mucosal breaks.

Regarding the relationship between the hernia length and esophageal acid exposure time, as many patients with a hernia length of 2 cm or greater on esophagography have an esophageal acid exposure time of 4% or higher [4], a hernia length of 2 cm or greater is often diagnosed clinically as HH.

In Japan, esophageal HH is diagnosed primarily by endoscopy, and a diagnosis of HH is made when the distance between the lower margin of the palisade vessels and the diaphragm hiatus is 2 cm or greater [6, 7]. It is

✉ Katsuhiko Iwakiri
k-iwa@nms.ac.jp

[1] Department of Gastroenterology, Nippon Medical School, Graduate School of Medicine, 1-1-5 Sendagi, Bunkyo-ku, Tokyo 113-8603, Japan

Published online: 26 October 2017

important to evaluate the palisade vessels during deep inspiration [8]. However, it remains unclear whether the diagnosis of HH is consistent between esophagography and endoscopy. A study examined the length of HH measured by esophagography and endoscopy, and demonstrated that only 57.4% of definite endoscopic HH with over 3 cm of gastric mucosa protrusion was regarded as definite HH by esophagography [9]. This suggests that endoscopic HH with a hernia length of 2 cm may not be detected as definite HH by esophagography. Thus, it is likely that the diagnosis of HH by endoscopy and esophagography is not consistent. In clinical practice, HHs with a hernia length of approximately 2 cm are also observed in many patients with no reflux symptoms during deep inspiration. However, they rarely exhibit esophageal mucosal breaks. We suspect that the endoscopic diagnosis of HH is not consistent with the manometric diagnosis, which is the gold standard for the diagnosis of HH. In this study, we evaluated the validity of endoscopic diagnosis of HH using high-resolution manometry, which is used for the definitive diagnosis of HH.

Methods

This study, which was carried out in Nippon Medical School Chiba Hokusoh Hospital between 1 March 2015 and 31 March 2016, was a prospective study to investigate the relationship between endoscopic and manometric HH in gastroesophageal reflux disease (GERD) patients with endoscopic HH under maintenance proton pump inhibitor (PPI) therapy, and was performed according to the ethical principles of the Declaration of Helsinki for medical research involving human subjects. The protocol employed was approved by the Ethics Committee of Nippon Medical School Chiba Hokusoh Hospital (no. 441). All subjects gave written informed consent prior to the study.

The study recruited 46 GERD patients (22 male, mean age: 62.4 years) with endoscopic HH with a hernia length greater than 1 cm on endoscopy under maintenance PPI therapy. Endoscopy was performed by sufficiently extending the esophagogastric junction (EGJ) by insufflation and deep inspiration before insertion of the endoscope into the stomach, and hernia length was measured as the distance to the lower margin of the palisade vessels in the 5–7 o'clock direction while withdrawing the endoscope from the location immediately above the hiatus. This procedure was repeated 3–5 times, and a reproducible length was regarded as the endoscopic hernia length, which was classified as 1–2, 2–3, 3–4, or 4–5 cm. The endoscopic hernia length between the hiatus and lower margin of the palisade vessels was 1–2 cm in 10 patients (5 male, mean age: 58.6 years), 2–3 cm in 17 (8 male, mean age: 60.5 years), 3–4 cm in 12 (6 male, mean age: 65.6 years), and 4–5 cm in 7 patients (3 male, mean age: 68.6 years).

For the manometric diagnosis of HH, all patients underwent high-resolution manometry (HRM: Starlet; Star Medical. Inc.). After patients had fasted for 6 h or longer, a manometry catheter with 36 channels at 1-cm intervals was inserted from the nostril into the stomach, and the pressures in the pharynx, esophagus, lower esophageal sphincter (LES), and proximal stomach were measured in the left recumbent position. After a 10-min accommodation following catheter insertion, 5 mL of water was swallowed, and the presence or absence of HH was evaluated 5–15 s later after the end of primary peristalsis. Water swallowing (5 mL) was repeated 10 times, and the mean and maximum hernia lengths were calculated. A diagnosis of manometric HH was made when the hernia length between the pulmonary inversion point (PIP), which indicates the location of the diaphragm, and lower margin of the LES, which is considered the lower end of the esophagus, was 2 cm or greater.

The manometric HH length in each group was presented as the median (25th to 75th percentile). The significance of the differences in hernia length among the groups was examined by Scheffé's test. A value of $P < 0.05$ was considered significant.

Results

Mean manometric hernia length on HRM in endoscopic HH

The mean manometric hernia length on HRM was 0 cm (0–0), 0 cm (0–0), 0.5 cm (0–1.1), and 2.2 cm (1.3–2.5) in the endoscopic HH groups with hernia lengths of 1–2, 2–3, 3–4, and 4–5 cm, respectively. The mean manometric hernia length significantly increased in the endoscopic HH group with a hernia length of 4–5 cm compared with the other groups, but did not differ significantly among the 1–2, 2–3, and 3–4 cm groups (Fig. 1). Manometric HH was confirmed in 1 of the 12 patients in the endoscopic HH group with a hernia length of 3–4 cm and in 4 of the 7 patients in the endoscopic HH group with a hernia length of 4–5 cm.

Maximum manometric hernia length on HRM in endoscopic HH

The maximum manometric hernia length on HRM was 0 cm (0–0), 0 cm (0–0), 0.8 cm (0–1.4), and 2.4 cm (1.5–2.9) in the endoscopic HH groups with hernia lengths of 1–2, 2–3, 3–4, and 4–5 cm, respectively. The maximum manometric hernia length in the endoscopic HH with

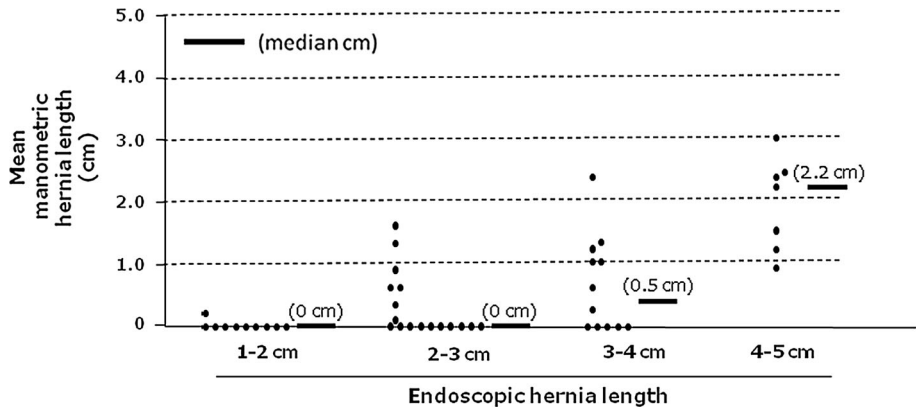

Fig. 1 Endoscopic hiatus hernia and mean manometric hiatus hernia length

hernia length of 4–5 cm group was significantly greater than in the other groups, but there was no significant difference among the 1–2, 2–3, or 3–4 cm groups (Fig. 2). Manometric HH was confirmed in 1 of the 12 patients in the endoscopic HH group with hernia length of 3–4 cm and in 5 of the 7 patients in the endoscopic HH group with hernia length of 4–5 cm.

Discussion

HH is defined as a displacement of the LES from the diaphragmatic hiatus into the chest. Although esophageal manometry is the optimal method for its evaluation, most HHs are currently detected during endoscopy. However, little is known about the relationship between endoscopic and manometric detection of HH.

Endoscopic diagnosis of HH was made by measuring the hernia length between the hiatus and the lower margin of the palisade vessels. It is important to perform the evaluation of the palisade vessels under deep inspiration. In patients with severe reflux esophagitis with esophageal mucosal breaks, it is difficult to evaluate the lower margin of palisade vessels. Although the pattern of the palisade vessels may be irregular and inconsistent after the healing of mucosal breaks in patients with severe reflux esophagitis, the location of the lower margin of palisade vessels can be determined. Therefore, we can diagnose hiatus hernia in all patients with severe reflux esophagitis.

HH cannot be evaluated by conventional manometry using a sleeve sensor, because it measures the maximum pressure at given time intervals in 6-cm segments across the EGJ, and cannot separately measure the high-pressure zones associated with the LES and the diaphragm. However, HH can be diagnosed more accurately by HRM, which can detect the high-pressure zones in the LES and diaphragm separately by measuring the pressure from the lower esophagus to the proximal part of the stomach using pressure sensors arranged at 1-cm intervals [10, 11]. In this study, we evaluated the validity of the endoscopic diagnosis of HH using HRM, which is the most reliable method for diagnosing HH.

In endoscopic HHs with a hernia length of 1–2 cm, the mean and maximum manometric hernia lengths were less than 1 cm, and no manometric HH was observed. In the endoscopic HHs with a hernia length of 2–3 or 3–4 cm, the mean and maximum manometric hernia lengths were also less than 1 cm, and HHs with a hernia length of 2 cm or greater, which are often associated with abnormal esophageal acid exposure, were not observed. Figure 3 shows

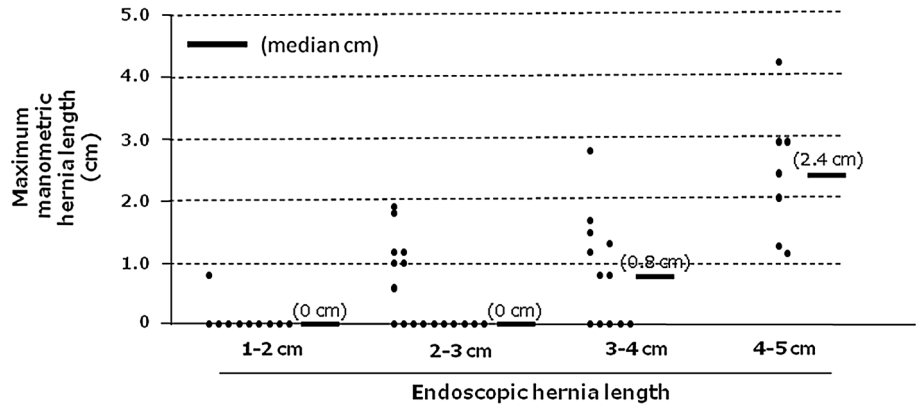

Fig. 2 Endoscopic hiatus hernia and maximum manometric hernia length

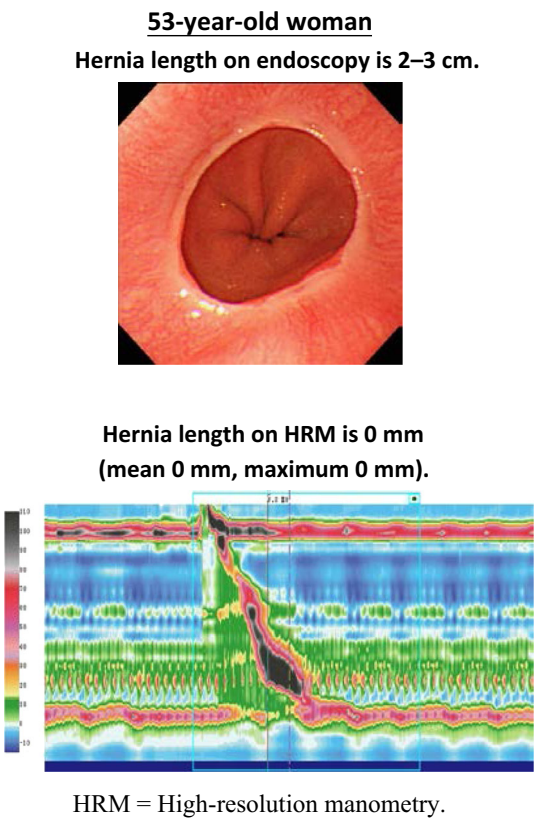

Fig. 3 Endoscopy and esophageal high-resolution manometry in a patient with endoscopic hiatus hernia with a hernia length of 2–3 cm. *HRM* high-resolution manometry

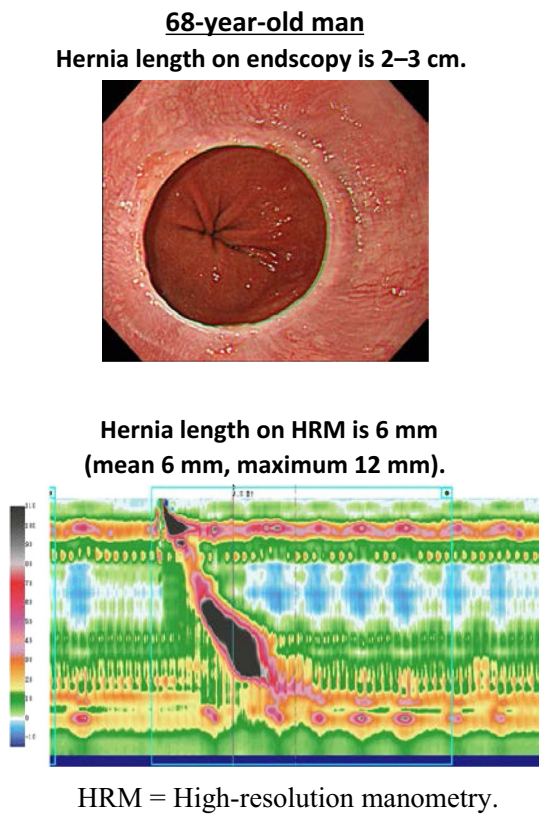

Fig. 4 Endoscopy and esophageal high-resolution manometry in a patient with endoscopic hiatus hernia with a hernia length of 2–3 cm. *HRM* high-resolution manometry

the endoscopic findings and results of HRM in an endoscopic HH patient with a hernia length of 2–3 cm, and no HH was detected on HRM. Figure 4 also shows the endoscopic findings and results of HRM in an endoscopic HH patient with a hernia length of 2–3 cm. Manometrically, the hernia length was 6 mm; therefore, the endoscopic and manometric diagnoses were different. In endoscopic HH patients with a hernia length of 4–5 cm, the mean and maximum hernia lengths are > 2 cm on HRM. In practice, 1 of 12 patients with endoscopic HH with a hernia length of 3–4 cm had manometric HH with mean and maximum hernia lengths of > 2 cm, 4 of 7 patients with endoscopic HH with a hernia length of 4–5 cm had manometric HH with a mean hernia length of > 2 cm, and 5 of 7 patients had manometric HH with a maximum hernia length of > 2 cm. Moreover, the hernia length was significantly greater in the endoscopic HH group with a hernia length of 4–5 cm than in groups with hernia lengths of < 4 cm. However, as there was no significant difference in hernia length among the endoscopic HH groups with hernia length of < 4 cm, endoscopically, HH with a hernia length of 4 cm or greater was considered significant.

Diaphragm displacement during deep inspiration may be involved in this overdiagnosis of HH by endoscopy. Figure 5 shows displacement of the diaphragm during deep inspiration. In this patient, the length between the lower margin of the LES and PIP was 22 mm at the end of expiration during rest, indicating the presence of HH with a hernia length of 22 mm. In this state, deep inspiration induces a 23-mm downward shift of the diaphragm, indicating HH with a hernia length of 45 mm. This diaphragm displacement during deep inspiration is likely the cause of overdiagnosis of HH. Expansion of the stomach due to air insufflation can also lead to the overdiagnosis of HH. Figure 6 shows a patient with HH with a hernia length of approximately 20 mm observed on endoscopy during deep inspiration. When the EGJ was examined by fixing the endoscope for a period of 1 min after deep inspiration, the HH with a hernia length of approximately 20 mm gradually contracted and nearly disappeared. A similar HH with a hernia length of 20 mm appeared again on repetition of deep inspiration. This indicates that approximately 20 mm of the gastric mucosa prolapses across the hiatus during deep inspiration. The results of this study suggest that endoscopic diagnosis of HH during deep inspiration is incorrect. In Japan, examination for Barrett's esophagus is performed with the lower esophagus sufficiently extended by deep inspiration. This method, which exposes the

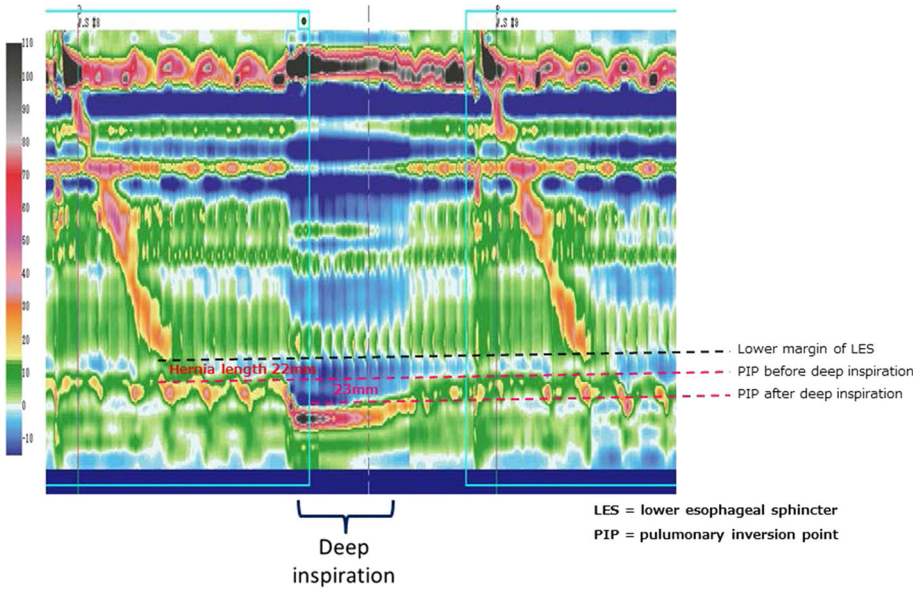

Fig. 5 Displacement of the diaphragm after deep inspiration in a patient with hiatus hernia with a hernia length of 22 mm at rest. The diaphragm was displaced downward by 23 mm during deep inspiration, and a hiatus hernia with a hernia length of 45 mm was observed

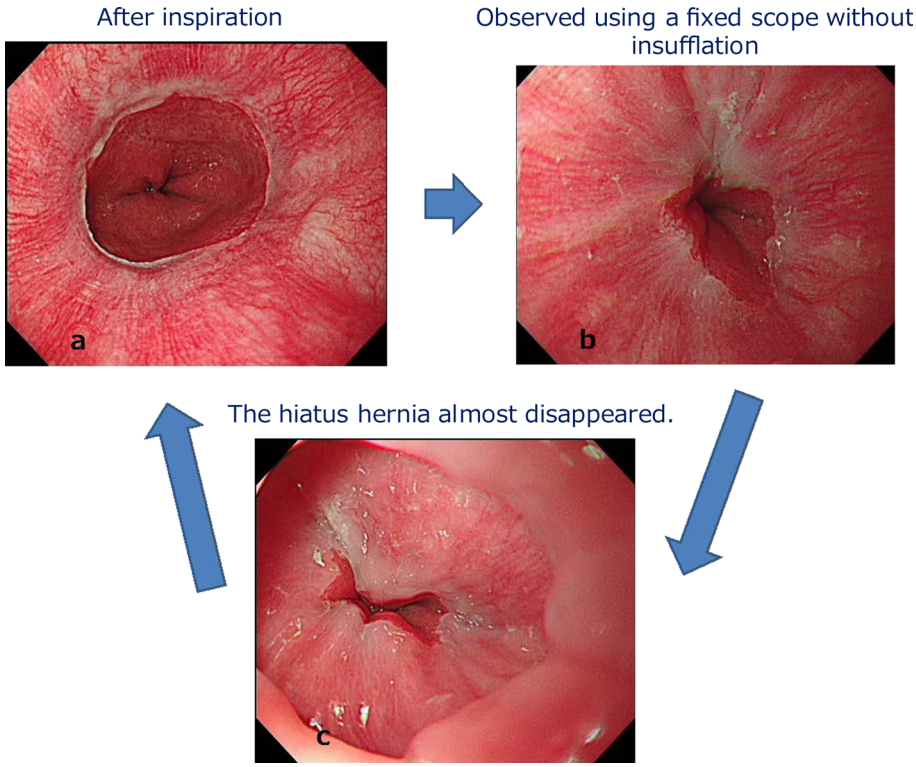

Fig. 6 Change in hiatus hernia during usual respiration in an endoscopic hiatus hernia patient with a hernia length of approximately 2 cm during deep inspiration. A hiatus hernia with a hernia length of approximately 2 cm was observed after deep inspiration (**a**). Observation using a fixed scope without insufflation during normal respiration. The hiatus hernia regressed (**b**), then disappeared (**c**), and the hiatus hernia with a hernia length of 2 cm appeared again on deep inspiration

palisade vessels, is useful for examination of Barrett's mucosa, but according to our results it is likely to lead to overdiagnosis of HH. Diagnosis of HH during expiration at rest may be recommended. In the future, we would like to perform esophageal pH monitoring in patients with HH diagnosed endoscopically during deep inspiration, clarify the relationship between the hernia length and abnormal esophageal acid exposure time, and validate our hypothesis, as well as establish an endoscopic diagnostic method for HH with abnormal esophageal acid exposure.

Although the major mechanism of acid reflux is transient LES relaxation, transient LES relaxation is not always accompanied by acid reflux [12–15]. With regard to the difference in proportion of acid reflux during transient LES relaxation [12–15], the location of the acid pocket, which is the layer of acid that appears postprandially above the dietary layer immediately below the EGJ as the source of

postprandial acid reflux, is considered to be very important [16, 17]. When the acid pocket is located in the hernia sac (supradiaphragmatic location), the proportion of acid reflux episodes during transient LES relaxation (70–85%) is significantly higher than when it is located below the diaphragm (7–20%) [18]. Retention of gastric acid in the HH means that the HH is of considerable size on endoscopy and has a hernia sac. Considering this, the endoscopic diagnostic criteria of hernia length greater than 4 cm may be appropriate, and HHs with no hernia sac may have little pathological significance.

Endoscopic examination during deep inspiration leads to overdiagnosis of HH. Of the endoscopic HHs with a hernia length of approximately 2 cm during deep inspiration, there were no manometric HHs with a hernia length greater than 2 cm. Manometric HH with a hernia length of approximately 2 cm was often endoscopic HH with a hernia length greater than 4 cm.

Acknowledgements We would like to thank Dr. Yoshio Hoshihara for his helpful advice on our manuscript.

Compliance with ethical standards

Conflict of interest The authors declare that they have no conflict of interest.

References

1. Iwakiri K, Kinoshita Y, Habu Y, et al. Evidence-based clinical practice guidelines for gastroesophageal reflux disease 2015. J Gastroenterol. 2016;51:751–67.
2. Sontag SJ, Schnell TG, Miller TQ, et al. The importance of hiatal hernia in reflux esophagitis compared with lower esophageal sphincter pressure or smoking. J Clin Gastroenterol. 1991;13:628–43.
3. Mishima I, Adachi K, Arima N, et al. Prevalence of endoscopically negative and positive gastroesophageal reflux disease in the Japanese. Scand J Gastroenterol. 2005;40:1005–9.
4. Jones MP, Sloan SS, Jovanovic B, et al. Impaired egress rather than increased access: an important independent predictor of erosive oesophagitis. Neurogastroenterol Motil. 2002;14:625–31.
5. Johnson LF, Demeester TR. Twenty-four-hour pH monitoring of the distal esophagus. A quantitative measure of gastroesophageal reflux. Am J Gastroenterol. 1974;62:325–32.
6. Iwakiri K, Hayashi Y, Kotoyori M, et al. Transient lower esophageal sphincter relaxations (TLESRs) are the major mechanism of gastroesophageal reflux but are not the cause of reflux disease. Dig Dis Sci. 2005;50:1072–7.
7. Iwakiri K, Tanaka Y, Hayashi Y, et al. Association between reflux esophagitis and/or hiatus hernia and gastric mucosal atrophy level in Japan. J Gastroenterol Hepatol. 2007;22:2212–6.
8. Hoshihara Y, Kogure T. What are longitudinal vessels? Endoscopic observation and clinical significance of longitudinal vessels in the lower esophagus. Esophagus. 2006;3:145–50.
9. Makuuchi H. Clinical study of esophageal hiatal hernia—diagnostic criteria and degree classification of hiatal hernia. Nihon Shokakibyou Gakkai Zasshi. 1982;79:1557–67.
10. Bredenoord AJ, Weusten BL, Carmagnola S, et al. Double-peaked high-pressure zone at the esophagogastric junction in controls and in patients with a hiatal hernia: a study using high-resolution manometry. Dig Dis Sci. 2004;49:1128–35.
11. Bredenoord AJ, Weusten BL, Timmer R, et al. Intermittent spatial separation of diaphragm and lower esophageal sphincter favors acidic and weakly acidic reflux. Gastroenterology. 2006;130:334–40.
12. Iwakiri K, Hoshino S, Kawami N. Mechanisms underlying excessive esophageal acid exposure in patients with gastroesophageal reflux disease. Esophagus. 2017;14:221–8.
13. Hayashi Y, Iwakiri K, Kotoyori M, et al. Mechanisms of acid gastroesophageal reflux in the Japanese population. Dig Dis Sci. 2008;53:1–6.
14. Iwakiri K, Kawami N, Sano H, et al. Mechanisms of excessive esophageal acid exposure in patients with reflux esophagitis. Dig Dis Sci. 2009;54:1686–92.
15. Sano H, Iwakiri K, Kawami N, et al. Mechanisms of acid reflux and how refluxed Acid extends proximally in patients with non-erosive reflux disease. Digestion. 2014;90(108–15):8.
16. Fletcher J, Wirz A, Young J, et al. Unbuffered highly acidic gastric juice exists at the gastroesophageal junction after a meal. Gastroenterology. 2001;121:775–83.
17. Kahrilas PJ, McColl K, Fox M, et al. The acid pocket: a target for treatment in reflux disease? Am J Gastroenterol. 2013;108:1058–64.
18. Beaumont H, Bennink RJ, de Jong J, et al. The position of the acid pocket as a major risk factor for acidic reflux in healthy subjects and patients with GORD. Gut. 2010;59:441–51.