

REVIEW ARTICLE

Julie R. Ingelfinger, M.D., *Editor*

Eosinophilic Esophagitis

Glenn T. Furuta, M.D., and David A. Katzka, M.D.

From the Department of Pediatrics, Section of Gastroenterology, Hepatology, and Nutrition, University of Colorado School of Medicine, and the Gastrointestinal Eosinophilic Diseases Program, Mucosal Inflammation Program, Digestive Health Institute, Children's Hospital Colorado, Aurora (G.T.F.); and the Division of Gastroenterology and Hepatology, Mayo Clinic, Rochester, MN (D.A.K.). Address reprint requests to Dr. Katzka at the Division of Gastroenterology and Hepatology, Mayo Clinic, 200 First Ave. SW, Rochester, MN 55905, or at katzka.david@mayo.edu.

N Engl J Med 2015;373:1640-8.

DOI: 10.1056/NEJMra1502863

Copyright © 2015 Massachusetts Medical Society.

ONCE CONSIDERED A RARE CONDITION, EOSINOPHILIC ESOPHAGITIS IS now one of the most common conditions diagnosed during the assessment of feeding problems in children and during the evaluation of dysphagia and food impaction in adults.¹ The entity exists worldwide but has been most extensively studied in Western countries, where its prevalence has been estimated to be 0.4% among all children and adults.² Whether eosinophilic esophagitis is truly a new disease or simply a recently recognized one is uncertain.³ In this review, we consider the diagnostic criteria, pathophysiological and clinical features, and treatment of this increasingly prevalent disease.

DEFINITION AND DIFFERENTIAL DIAGNOSIS

Esophageal eosinophilia was initially considered solely a manifestation of gastroesophageal reflux disease (GERD). However, in the mid-1990s, experienced clinicians identified esophageal eosinophilia in both adults and children who had other symptoms. Neither the clinical symptoms nor the histologic changes in these patients responded to acid suppression and antireflux surgery, which suggested that the condition was distinct from GERD. Two studies of case series^{4,5} and evidence of the resolution of esophageal eosinophilia in response to therapy with an elemental-formula diet⁶ suggested that eosinophilic esophagitis was a unique entity. However, clear diagnostic criteria were lacking.

More recently, evaluation and treatment recommendations have been developed on the basis of clinical experiences from different medical subspecialties and the increasing body of knowledge derived from clinical and basic research.^{7,8} Eosinophilic esophagitis is currently defined as a chronic, immune-mediated or antigen-mediated esophageal disease characterized by symptoms related to esophageal dysfunction and eosinophil-predominant inflammation. The dominant antigens that mediate this disease appear to be food-based. Clinically, eosinophilic esophagitis is defined by several components. First, symptoms include — but are not limited to — feeding problems, vomiting, and abdominal pain in children and dysphagia and food impaction in adolescents and adults. Second, esophageal mucosal eosinophilia of at least 15 eosinophils per high-power field is present. Other causes of these findings, particularly GERD, must be ruled out.^{7,8} However, GERD may be difficult to rule out, because neither the response to proton-pump inhibitors nor the duration of exposure to esophageal acid, measured by means of ambulatory pH monitoring, definitively distinguishes GERD from eosinophilic esophagitis.⁹ Other causes of esophageal eosinophilia (e.g., parasitic infection, allergic vasculitis, esophageal leiomyomatosis, and Crohn's disease of the esophagus) are rare.

PATHOGENESIS

ENVIRONMENTAL FACTORS CONFERRING A PREDISPOSITION TO EOSINOPHILIC ESOPHAGITIS

The increasing prevalence of eosinophilic esophagitis has focused attention on environmental exposures. Birth by cesarean section, premature delivery, antibiotic exposure during infancy, food allergy, lack of breast-feeding, and living in an area of lower population density have all been associated with eosinophilic esophagitis,^{10,11} which may imply that altered stimulation of the immune system at an early age confers a predisposition to this disease. Studies have also suggested that a lack of early exposure to microbes¹¹ and an altered microbiome may play a role, as has been suggested for other atopic diseases, such as asthma and atopic dermatitis.¹² There is speculation that these exposures early in life create an epigenetic signature that increases the probability of developing eosinophilic esophagitis.

GENETIC PREDISPOSITION

The male predominance of eosinophilic esophagitis, as well as studies of family history and twin concordance and genomewide association studies, suggest that there is a genetic component to eosinophilic esophagitis. In almost every study, male sex has a 3:1 preponderance.¹³ A family history of eosinophilic esophagitis is frequently reported, with the heritability risk estimated to be 2% on the basis of results from a nuclear family-based cohort of 914 probands with eosinophilic esophagitis and 63 twin probands.¹⁴ Genomewide association studies have reported three genes with proposed functional sequelae (the genes encoding thymic stromal lymphopoietin,¹⁵ eotaxin-3 [also called chemokine C-C motif ligand 26],¹⁶ and calpain-14^{17,18}) as being altered in eosinophilic esophagitis.

IMPAIRED BARRIER FUNCTION

Assessment of esophageal tissues from patients with eosinophilic esophagitis has revealed a striking pattern of dilated interepithelial spaces,¹⁹ altered epithelial barrier function,²⁰ and down-regulation of proteins associated with barrier function (filaggrin and zonulin-1¹⁹) and adhesion molecules (desmoglein-1²¹) (Fig. 1). Interleukin-13 has been shown to down-regulate desmoglein-1²¹ and fil-

aggrin²² in vitro. Altered epithelial permeability²³ can lead to a permissive environment that enhances antigen presentation, which in turn leads to recruitment of eosinophils.

ENHANCED TH2 ACTIVITY AND ALLERGIC SUSCEPTIBILITY

Several lines of evidence support the concept that eosinophilic esophagitis is an entity mediated by type 2 helper T (Th2) cell activity and induced primarily by food antigens. Studies of case series have repeatedly reported that patients with eosinophilic esophagitis have environmental and food hypersensitivity, have a response to dietary elimination of food antigens, and have a relapse with reintroduction of similar food antigens.^{6,24} Whereas food antigens are primarily identified as the allergic triggers, inhaled aeroallergens have also been implicated in some patients; this finding may represent a manifestation of cross-sensitization to food allergens.²⁵ Indeed, murine models of eosinophilic esophagitis can be induced by sensitizing and challenging mice with aeroallergens and ovalbumin^{26,27} or by overexpressing the cytokines seen in human eosinophilic esophagitis in the animals.²⁸ Several lines of evidence suggest that interleukin-5 and interleukin-13 may play a role in the pathogenesis of eosinophilic esophagitis. Interleukin-5–null mice develop less esophageal eosinophilia in allergen-induced models, as compared with wild-type mice. Interleukin-13 is overexpressed in biopsy specimens from patients with eosinophilic esophagitis and has been found to regulate a number of related cytokines in *in vitro* studies²² and in studies of mice. In addition, separate prospective trials have shown that treatment with anti-interleukin-5 or anti-interleukin-13 antibodies reduces numbers of esophageal eosinophils in children and adults.^{29,30} There are also cytokine-directed and thymic stromal lymphopoietin-directed proliferation and recruitment of eosinophils, IgE-bearing mast cells,³¹ Th2 lymphocytes,³² basophils³³ and natural killer cells³⁴ in patients with eosinophilic esophagitis.

The predominant mechanism of food allergy in eosinophilic esophagitis appears to be a non-IgE-mediated process, because omalizumab, an anti-IgE biologic treatment, is not effective in humans,³⁵ esophageal eosinophilia can develop in IgE-null and B-cell-null mice,³⁶ and IgE-based

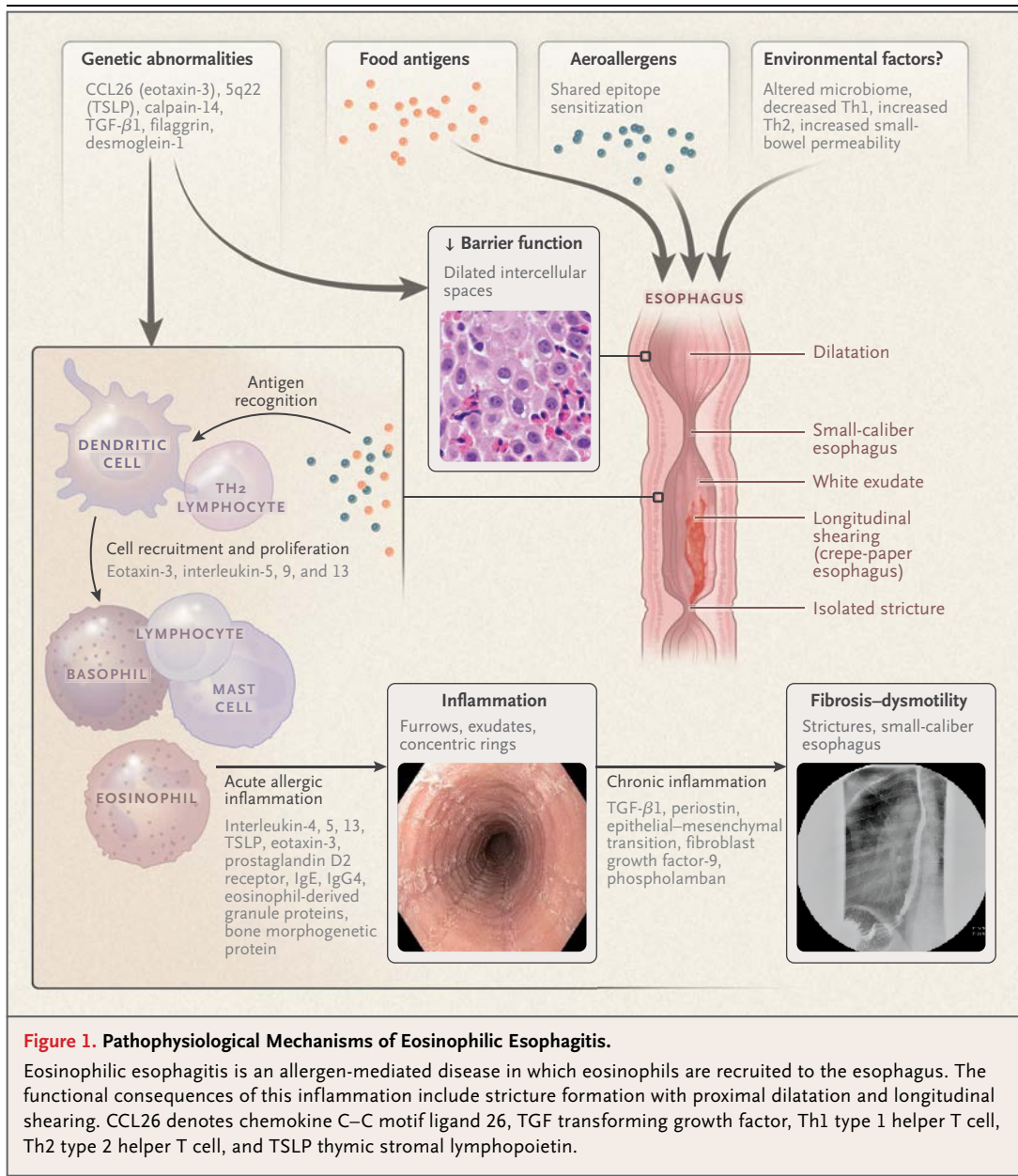


Figure 1. Pathophysiological Mechanisms of Eosinophilic Esophagitis.

Eosinophilic esophagitis is an allergen-mediated disease in which eosinophils are recruited to the esophagus. The functional consequences of this inflammation include stricture formation with proximal dilatation and longitudinal shearing. CCL26 denotes chemokine C–C motif ligand 26, TGF transforming growth factor, Th1 type 1 helper T cell, Th2 type 2 helper T cell, and TSLP thymic stromal lymphopoietin.

skin testing does not consistently identify food-antigen triggers.³⁷ Food-specific IgG4 was recently shown to be present in the esophageal epithelium and to be reactive to the four most common food-antigen triggers in patients with eosinophilic esophagitis³⁸

ESOPHAGEAL DYSFUNCTION AND FIBROTIC POTENTIAL

An intraluminal balloon device that is used to assess esophageal stricturing and fibrosis by mea-

suring wall compliance may be useful even when stricturing and fibrosis are not detectable endoscopically.³⁹ Early studies with that device showed that patients with a specific distensibility plateau were less likely to have a history of food impaction or to have food impaction during follow-up evaluation. Contrast esophagography in patients with abnormal esophageal-wall compliance often reveals that the esophageal caliber is decreased and the esophagus is diffusely less distensible.⁴⁰ In vitro exposure of esophageal fibroblasts and

smooth-muscle cells to transforming growth factor β (TGF- β) leads to smooth-muscle contraction and fibrosis.⁴¹⁻⁴³

CLINICAL FEATURES

EPIDEMIOLOGY

Since the establishment of diagnostic guidelines and a diagnostic code (*International Classification of Diseases, Ninth Revision*, code 530.13; *International Classification of Diseases, Tenth Revision*, code K20.0), some studies have estimated the prevalence of eosinophilic esophagitis as between 1 and 5 per 10,000 persons in the United States and Europe, with an increasing prevalence in Asia.⁴⁴⁻⁴⁷ Certain subpopulations, such as patients who are undergoing endoscopy for a history of food impaction, have a markedly higher prevalence, of up to 54%.⁴⁸

Eosinophilic esophagitis has been described in all age groups, but it predominantly affects white men, with an onset from school age to midlife.⁴⁶ A personal or family history of atopic disorders, such as asthma, eczema, rhinitis, and anaphylactic food allergy, is common, and these conditions require treatment.⁴⁹

CLINICAL PRESENTATION

Children may have a wide variety of nonspecific symptoms, including feeding difficulty, nausea and vomiting, heartburn, and failure to thrive. In contrast, teenagers and adults are more likely to present with dysphagia and episodes of food impaction. Nevertheless, patients of different age groups may have symptoms in common — for example, chronic reflux symptoms. Symptoms may be underestimated as a result of long-standing and subtle accommodation, such as eating slowly, chewing carefully, cutting food into small pieces, lubricating foods with sauces, drinking liquids to dilute foods, and avoiding pills and foods likely to cause dysphagia, such as meats and breads. Patients may be afraid to eat in public places, worrying that they will have difficulty eating. In rare cases, eosinophilic esophagitis may manifest with spontaneous rupture of the esophagus from forceful retching (Boerhaave's syndrome) after a food impaction. Heartburn, especially with the ingestion of alcohol, occurs in 30% of adult patients.^{13,50} It is unclear whether years of unrecognized childhood subclinical disease or "silent" chronic inflammation precede presentation in adults who have eosinophilic esophagitis

or whether adult patients truly have late onset of the disease or a different pathogenesis or phenotype of the disease. In support of the hypothesis that unrecognized childhood subclinical disease or silent chronic inflammation precedes presentation in adults are results from a natural history study in which it was observed that 85% of adults who had untreated symptoms for 20 years presented with esophageal strictures.⁵¹

IMAGING IN EOSINOPHILIC ESOPHAGITIS

Endoscopy and contrast radiography provide complementary tools for the assessment of the esophagus in eosinophilic esophagitis (Fig. S1 in the Supplementary Appendix, available with the full text of this article at NEJM.org). The most common endoscopic findings are white specks (representative of eosinophilic exudates), mucosal edema, linear furrows, esophageal rings, and strictures.^{52,53} Chronic remodeling is represented by strictures; a so-called "crepe-paper esophagus," in which linear tears occur in response to minimal trauma, such as passage of the endoscope⁵⁰; and the "tug sign," a firm feeling sensed by the endoscopist when performing an esophageal biopsy.⁵⁴ A validated endoscopic scoring system was recently developed to standardize the assessment of eosinophilic esophagitis signs that scores the presence of edema, rings, exudates, furrows, and strictures (EREFS).⁵²

The recognition of eosinophilic esophagitis as a diagnostic entity has led to increased use of barium esophagography to evaluate the esophageal lumen in patients with dysphagia. In contrast to the focal distal esophageal strictures found in patients with GERD, strictures in patients with eosinophilic esophagitis may be lengthy and tapered and commonly escape detection during endoscopy but are evident in contrast esophagrams. Two recent studies reported that 71% of adults and 55% of children with eosinophilic esophagitis did not have esophageal narrowing recognized at the time of endoscopy but did have evidence of narrowing at the time of esophagography.^{55,56}

HISTOLOGIC CHARACTERISTICS OF EOSINOPHILIC ESOPHAGITIS

An increased number of eosinophils in the esophageal epithelium, which is a mucosa that is typically devoid of eosinophils, is the histologic hallmark of eosinophilic esophagitis (Fig. 2). A cutoff value of at least 15 eosinophils per high-power

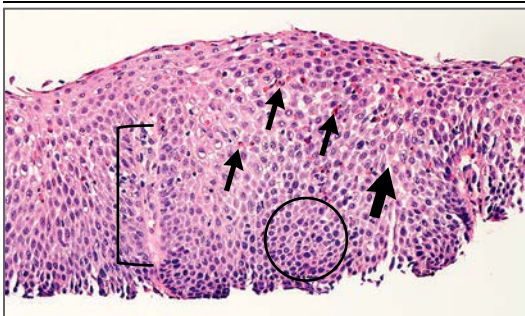


Figure 2. Histologic Characteristics of Eosinophilic Esophagitis.

Routine staining with hematoxylin and eosin reveals numerous eosinophils (thin arrows), dilated intercellular spaces (thick arrow), basal zone hyperplasia (circle), and papillary elongation (bracket).

field is thought to approach a sensitivity of 100% and specificity of 96% for establishing the histologic diagnosis of eosinophilic esophagitis,⁵⁷ although patients with lower levels of eosinophilia and phenotypic features of eosinophilic esophagitis have been described.⁵⁸ Characteristic, but not pathognomonic, features include aggregates of eosinophils or microabscess and eosinophil layering along the luminal surface. Other associated patterns of injury include dilated intercellular spaces, rete-peg elongation, and basal-cell hyperplasia.⁵⁹ Numbers of inflammatory cells, including lymphocytes, mast cells, and basophils, are also increased in the affected epithelial space.^{33,60}

ASSOCIATED COMPLICATIONS AND CONDITIONS

Complications that may occur in association with eosinophilic esophagitis include esophageal stricture, food impaction, perforation, and malnutrition but not cancer. A number of coexisting conditions have been associated with patients with esophageal eosinophilia, including connective-tissue diseases,⁶¹ celiac disease,⁶² and Crohn's disease.⁶³

TREATMENT

IDENTIFICATION OF VALIDATED TREATMENT END POINTS

Patients with eosinophilic esophagitis may have a mismatch between symptoms and histopathologic features, which creates the need for multiple assessments of disease activity.⁶⁴ As a result, the short-term treatment goals include the alleviation of symptoms, control of inflammation,

and restoration of function. Three approaches can be used to reach these goals: diet, drugs, and dilation.⁶⁵ When possible, therapy should be provided with a team approach that includes a gastroenterologist, an allergist, and a nutritionist.

DIET

In 1995, a study described the favorable effects of an exclusive amino acid–based formula diet (i.e., one devoid of food antigens) in the treatment of 10 children with eosinophilic esophagitis.⁶ Both the symptoms and the histologic abnormalities improved, but they recurred after resumption of a normal diet. This small study was followed by much larger studies⁶⁶ and by a similar study involving adults⁶⁷; in these studies, the patients had a near complete response to therapy, and the stage was set for the routine use of diet therapy in the treatment of eosinophilic esophagitis. The expense and lack of patient interest in an elemental diet led to the development of two other diet strategies (Table 1). The use of skin-prick, atopy-patch, or specific serum IgE testing performed by an allergist to determine targeted diets has been shown to have a high degree of success in children; however, more recent work indicates that this approach may not be as effective as initially thought, with only 45% of patients having a sustained response.⁶⁸ Nevertheless, elimination diets and the avoidance of food anaphylaxis as directed by an allergist are reasonable treatment options. An alternative diet treatment does not rely on food-allergy testing but rather eliminates the six most commonly identified types of allergenic food (wheat, milk, soy, nuts, eggs, and seafood). This so-called six-food elimination diet was found to improve symptoms and histologic abnormalities in up to 26 of 35 children⁶⁹ and 32 of 50 adults³⁷ within 6 weeks. Follow-up studies are evaluating a less stringent approach in which fewer foods are initially eliminated.⁷⁰

Diet therapy can be highly effective and can directly address the underlying allergic mechanism. It may also achieve the goal of identifying a limited number of food antigens that trigger the inflammatory response. For example, because endoscopy with biopsy is currently the only reliable method for the assessment of histologic response, individual patients may undergo multiple endoscopic examinations in an attempt to identify the foods that trigger esophageal eosinophilia.⁷¹ Less-invasive testing with a swallowed sponge admin-

istered bedside without anesthesia is currently being studied.⁷² The increased cost of food, poor adherence, and nutritional deficiencies due to the elimination of foods are concerns with diet therapy.

DRUGS

Proton-Pump Inhibitors

Proton-pump inhibitors may play a role in the diagnostic evaluation of patients with suspected eosinophilic esophagitis and in the care of those with the disease. First, a lack of response to proton-pump inhibitors is currently the only criterion available to rule out GERD as a cause of esophageal eosinophilia. Second, patients with well-established eosinophilic esophagitis can also have symptomatic GERD that is responsive to proton-pump inhibitor treatment and contributes to the development of eosinophilic esophagitis. Third, *in vitro* studies show that proton-pump inhibitors decrease cytokine secretion from the esophageal epithelium independently of their effect on acid secretion, which leads to the hypothesis that proton-pump inhibitors may provide an antiinflammatory benefit.⁷³ These *in vitro* studies have further defined a subgroup of patients with an eosinophilic esophagitis phenotype in which the esophageal eosinophilia responded to proton-pump inhibitors, a phenomenon termed proton-pump inhibitor-responsive esophageal eosinophilia. Further study of patients with proton-pump inhibitor-responsive esophageal eosinophilia has shown that they have clinical, histologic, and genetic characteristics similar to those of patients with eosinophilic esophagitis, which supports the possibility that the condition is a subtype of eosinophilic esophagitis.^{60,74-76} Nevertheless, the response to proton-pump inhibitors, in contrast to being completely driven by food allergies, may differentiate proton-pump inhibitor-responsive esophageal eosinophilia from eosinophilic esophagitis.

Topical Glucocorticoids

Glucocorticoids target key mechanisms in eosinophilic esophagitis. For example, glucocorticoids decrease fibrosis through the reduction of inflammatory cells.⁷⁷ Furthermore, increased levels of interleukin-13 (a central regulator of allergic diseases) messenger RNA and the eosinophilic esophagitis transcriptome are largely reversible with glucocorticoid treatment *in vivo*.⁷⁸ Although it has

Table 1. Medical Treatment of Active Eosinophilic Esophagitis.

Method	Specific Recommendation or Dosage
Elemental diet therapy	—
Elimination diet therapy	
Six-food elimination	Elimination of milk, wheat, eggs, soy, seafood, and nuts
Four-food elimination	Elimination of milk, wheat, eggs, and soy
Allergy testing–based	Elimination of foods on the basis of results of radioallergosorbent testing, skin-prick testing, or atopy-patch testing*
Omeprazole (proton-pump inhibitor)†	Children with body weight 10 to 20 kg: 10 mg twice a day Children with body weight >20 kg: 20 mg twice a day Adults: 40 mg once or twice a day
Glucocorticoids	
Fluticasone	Children: 220 to 440 μ g twice a day Adults: 440 to 880 μ g twice a day
Budesonide	Children: 0.25 to 0.5 mg twice a day Adults: 1 to 2 mg twice a day

* Approximately 45% of patients have a sustained response to this type of diet therapy.⁶⁸

† An equivalent proton-pump inhibitor can be administered.

not been approved by the Food and Drug Administration, fluticasone administered orally as a spray from a metered-dose inhaler or a viscous preparation of liquid budesonide are the mainstays of pharmacologic therapy for eosinophilic esophagitis.⁷⁹⁻⁸⁴ The efficacy of these topical medications in improving symptoms and histologic abnormalities after 2 to 12 weeks of use ranges from 53%⁸¹ to 95%.^{64,82} Topical glucocorticoids may also reduce the frequency of subsequent food impactions.⁸³ One study has supported the observation that oral viscous budesonide has more prolonged contact with esophageal mucosa and coats a greater length of the esophagus than does nebulized budesonide.⁸⁴ Recent genomic analyses may help identify whether patients will be more or less likely to have a response to glucocorticoid treatment.⁷⁹ The potential side effects include local candida infection, adrenal axis suppression, bone demineralization, and diminished growth. Because swallowed topical glucocorticoids undergo first-pass metabolism, such effects appear to be uncommon.⁸⁵ Nevertheless, the use of systemic glucocorticoids to treat eosinophilic esophagitis leads to similar therapeutic results but incurs a greater risk of side effects than does the use of topical glucocorticoids.⁸⁰

DILATION

Esophageal dilation to alleviate esophageal narrowing is a commonly accepted therapy for eosinophilic esophagitis, particularly in older teenagers and adults. Whereas earlier reports suggested a high rate of complications related to dilation in patients with eosinophilic esophagitis, a review of several large series has shown perforation rates of less than 1% (3 of 992 dilations).⁸⁶ In patients with eosinophilic esophagitis, dilation should be performed gradually over multiple sessions, with an expectation that 75% of patients will have chest pain after the procedure (a course that differs from that in patients with GERD). Dilation successfully addresses the luminal narrowing that can complicate eosinophilic esophagitis but does not treat the underlying inflammatory process.

LONG-TERM COMPLICATIONS, QUALITY OF LIFE, AND MAINTENANCE THERAPY

One of the controversial questions in the management of eosinophilic esophagitis is the role of long-term maintenance therapy. The evidence to date indicates that eosinophilic esophagitis is a not premalignant disease and does not diminish life span. Furthermore, periods of prolonged spontaneous or dilation-induced symptomatic remission may occur without the need for dietary changes or medical therapy.⁸⁷ However, in most patients, eosinophilic esophagitis is a chronic disease, and if treatment is stopped, inflammation ensues and symptoms recur; quality of life, including vitality and general health scores, is subsequently diminished,⁸⁸ and complications

such as strictures may develop.⁵¹ Few studies have examined the long-term benefit of diet or topical glucocorticoid therapy in eosinophilic esophagitis, although both have been proposed as options for maintaining remission.⁸⁹ The expert consensus opinion is that evidence of chronic remodeling, as in patients with long strictures or a small-caliber esophagus, a history of food impactions or severe symptoms, or rapid recurrence of illness while not receiving therapy, indicates the need for maintenance therapy.^{7,8}

CONCLUSIONS

Since the initial description of eosinophilic esophagitis in case series more than 20 years ago, interest in it has burgeoned, and there is now a greater awareness of the clinical features, basic mechanisms, and effective therapeutic options. The advent of molecular characterizations and diagnostics will lead to the determination of new therapeutic strategies.⁹⁰ Progress in the treatment of eosinophilic esophagitis will require a better understanding of the implications of this chronic and probably lifelong disease, the development of new therapeutic approaches, and the documentation of the safety and efficacy of long-term therapies.

Dr. Furuta reports receiving consulting fees from Genentech and grant support from Morphotek and Nutricia, and is co-founder of EnteroTrack. Dr. Katzka reports that his laboratory has provided funding to Capnostics to develop an esophageal sponge. No other potential conflict of interest relevant to this article was reported.

Disclosure forms provided by the authors are available with the full text of this article at NEJM.org.

REFERENCES

1. Straumann A, Bussmann C, Zuber M, Vannini S, Simon HU, Schoepfer A. Eosinophilic esophagitis: analysis of food impaction and perforation in 251 adolescent and adult patients. *Clin Gastroenterol Hepatol* 2008;6:598-600.
2. Dellon ES. Epidemiology of eosinophilic esophagitis. *Gastroenterol Clin North Am* 2014;43:201-18.
3. Whitney-Miller CL, Katzka D, Furth EE. Eosinophilic esophagitis: a retrospective review of esophageal biopsy specimens from 1992 to 2004 at an adult academic medical center. *Am J Clin Pathol* 2009;131:788-92.
4. Attwood SEA, Smyrk TC, Demeester TR, Jones JB. Esophageal eosinophilia with dysphagia: a distinct clinicopathologic syndrome. *Dig Dis Sci* 1993;38:109-16.
5. Straumann A, Spichtin HP, Bernoulli R, Loosli J, Vöggtlin J. Idiopathic eosinophilic esophagitis: a frequently overlooked disease with typical clinical aspects and discrete endoscopic findings. *Schweiz Med Wochenschr* 1994;124:1419-29. (In German.)
6. Kelly KJ, Lazenby AJ, Rowe PC, Yardley JH, Perman JA, Sampson HA. Eosinophilic esophagitis attributed to gastroesophageal reflux: improvement with an amino acid-based formula. *Gastroenterology* 1995;109:1503-12.
7. Liacouras CA, Furuta GT, Hirano I, et al. Eosinophilic esophagitis: updated consensus recommendations for children and adults. *J Allergy Clin Immunol* 2011;128(1):3.e6-20.e6.
8. Dellon ES, Gonsalves N, Hirano I, Furuta GT, Liacouras CA, Katzka DA. ACG clinical guideline: evidenced based approach to the diagnosis and management of esophageal eosinophilia and eosinophilic esophagitis (EoE). *Am J Gastroenterol* 2013;108:679-92.
9. Molina-Infante J, Ferrando-Lamana L, Ripoll C, et al. Esophageal eosinophilic infiltration responds to proton pump inhibition in most adults. *Clin Gastroenterol Hepatol* 2011;9:110-7.
10. Jensen E, Hoffman K, Shaheen NJ, Genta RM, Dellon ES. Esophageal eosinophilia is increased in rural areas with low population density: results from a national pathology database. *Am J Gastroenterol* 2014;109:668-75.
11. Jensen ET, Kappelman MD, Kim HP, Ringel-Kulka T, Dellon ES. Early life exposures as risk factors for pediatric eosinophilic esophagitis. *J Pediatr Gastroenterol Nutr* 2013;57:67-71.
12. van Nimwegen FA, Penders J, Stobberingh EE, et al. Mode and place of delivery,

- gastrointestinal microbiota, and their influence on asthma and atopy. *J Allergy Clin Immunol* 2011;128(5):948.e3-55.e3.
13. Kapel RC, Miller JK, Torres C, Aksoy S, Lash R, Katzka DA. Eosinophilic esophagitis: a prevalent disease in the United States that affects all age groups. *Gastroenterology* 2008;134:1316-21.
 14. Alexander ES, Martin LJ, Collins MH, et al. Twin and family studies reveal strong environmental and weaker genetic cues explaining heritability of eosinophilic esophagitis. *J Allergy Clin Immunol* 2014;134(5):1084.e1-1092.e1.
 15. Sherrill JD, Gao PS, Stucke EM, et al. Variants of thymic stromal lymphopoietin and its receptor associate with eosinophilic esophagitis. *J Allergy Clin Immunol* 2010;126(1):160.e3-165.e3.
 16. Blanchard C, Wang N, Stringer KF, et al. Eotaxin-3 and a uniquely conserved gene-expression profile in eosinophilic esophagitis. *J Clin Invest* 2006;116:536-47.
 17. Sleiman PMA, Wang ML, Cianferoni A, et al. GWAS identifies four novel eosinophilic esophagitis loci. *Nat Commun* 2014;5:5593.
 18. Kottyan LC, Davis BP, Sherrill JD, et al. Genome-wide association analysis of eosinophilic esophagitis provides insight into the tissue specificity of this allergic disease. *Nat Genet* 2014;46:895-900.
 19. Katzka DA, Tadi R, Smyrk TC, et al. Effects of topical steroids on tight junction proteins and spongiosis in esophageal epithelia of patients with eosinophilic esophagitis. *Clin Gastroenterol Hepatol* 2014;12(11):1824.e1-1829.e1.
 20. van Rhijn BD, Weijenborg PW, Verheij J, et al. Proton pump inhibitors partially restore mucosal integrity in patients with proton pump inhibitor-responsive esophageal eosinophilia but not eosinophilic esophagitis. *Clin Gastroenterol Hepatol* 2014;12(11):1815.e2-1823.e2.
 21. Sherrill JD, Kc K, Wu D, et al. Desmoglein-1 regulates esophageal epithelial barrier function and immune responses in eosinophilic esophagitis. *Mucosal Immunol* 2014;7:718-29.
 22. Blanchard C, Stucke EM, Burwinkel K, et al. Coordinate interaction between IL-13 and epithelial differentiation cluster genes in eosinophilic esophagitis. *J Immunol* 2010;184:4033-41.
 23. Katzka DA, Ravi K, Geno DM, et al. Endoscopic mucosal impedance measurements correlate with eosinophilia and dilation of intercellular spaces in patients with eosinophilic esophagitis. *Clin Gastroenterol Hepatol* 2015;13(7):1242.e1-1248.e1.
 24. Markowitz JE, Spergel JM, Ruchelli E, Liacouras CA. Elemental diet is an effective treatment for eosinophilic esophagitis in children and adolescents. *Am J Gastroenterol* 2003;98:777-82.
 25. van Rhijn BD, van Ree R, Versteeg SA, et al. Birch pollen sensitization with cross-reactivity to food allergens predominates in adults with eosinophilic esophagitis. *Allergy* 2013;68:1475-81.
 26. Akei HS, Mishra A, Blanchard C, Rothenberg ME. Epicutaneous antigen exposure primes for experimental eosinophilic esophagitis in mice. *Gastroenterology* 2005;129:985-94.
 27. Cho JY, Doshi A, Rosenthal P, et al. Smad3-deficient mice have reduced esophageal fibrosis and angiogenesis in a model of egg-induced eosinophilic esophagitis. *J Pediatr Gastroenterol Nutr* 2014;59:10-6.
 28. Masterson JC, McNamee EN, Hosford L, et al. Local hypersensitivity reaction in transgenic mice with squamous epithelial IL-5 overexpression provides a novel model of eosinophilic oesophagitis. *Gut* 2014;63:43-53.
 29. Spergel JM, Rothenberg ME, Collins MH, et al. Reslizumab in children and adolescents with eosinophilic esophagitis: results of a double-blind, randomized, placebo-controlled trial. *J Allergy Clin Immunol* 2012;129(2):456.e1-463.e3.
 30. Rothenberg ME, Wen T, Greenberg A, et al. Intravenous anti-IL-13 mAb QAX576 for the treatment of eosinophilic esophagitis. *J Allergy Clin Immunol* 2015;135:500-7.
 31. Mulder DJ, Mak N, Hurlbut DJ, Justinich CJ. Atopic and non-atopic eosinophilic oesophagitis are distinguished by immunoglobulin E-bearing intraepithelial mast cells. *Histopathology* 2012;61:810-22.
 32. Straumann A, Bauer M, Fischer B, Blaser K, Simon HU. Idiopathic eosinophilic esophagitis is associated with a T(H)2-type allergic inflammatory response. *J Allergy Clin Immunol* 2001;108:954-61.
 33. Noti M, Wojno ED, Kim BS, et al. Thymic stromal lymphopoietin-elicited basophil responses promote eosinophilic esophagitis. *Nat Med* 2013;19:1005-13.
 34. Lexmond WS, Neves JF, Nurko S, et al. Involvement of the iNKT cell pathway is associated with early-onset eosinophilic esophagitis and response to allergen avoidance therapy. *Am J Gastroenterol* 2014;109:646-57.
 35. Rocha R, Vitor AB, Trindade E, et al. Omalizumab in the treatment of eosinophilic esophagitis and food allergy. *Eur J Pediatr* 2011;170:1471-4.
 36. Mishra A, Schlotman J, Wang MQ, Rothenberg ME. Critical role for adaptive T cell immunity in experimental eosinophilic esophagitis in mice. *J Leukoc Biol* 2007;81:916-24.
 37. Gonsalves N, Yang GY, Doerfler B, Ritz S, Ditto AM, Hirano I. Elimination diet effectively treats eosinophilic esophagitis in adults; food reintroduction identifies causative factors. *Gastroenterology* 2012;142(7):1451.e1-1459.e1.
 38. Clayton F, Fang JC, Gleich GJ, et al. Eosinophilic esophagitis in adults is associated with IgG4 and not mediated by IgE. *Gastroenterology* 2014;147:602-9.
 39. Nicodeme F, Hirano I, Chen J, et al. Esophageal distensibility as a measure of disease severity in patients with eosinophilic esophagitis. *Clin Gastroenterol Hepatol* 2013;11(19):1101.e1-1107.e1.
 40. Lee J, Huprich J, Kujath C, et al. Esophageal diameter is decreased in some patients with eosinophilic esophagitis and might increase with topical corticosteroid therapy. *Clin Gastroenterol Hepatol* 2012;10:481-6.
 41. Beppu LY, Anilkumar AA, Newbury RO, Dohil R, Broide DH, Aceves SS. TGF-beta1-induced phospholamban expression alters esophageal smooth muscle cell contraction in patients with eosinophilic esophagitis. *J Allergy Clin Immunol* 2014;134(5):1100.e4-1107.e4.
 42. Muir AB, Dods K, Noah Y, et al. Esophageal epithelial cells acquire functional characteristics of activated myofibroblasts after undergoing an epithelial to mesenchymal transition. *Exp Cell Res* 2015;330:102-10.
 43. Kagalwalla AF, Akhtar N, Woodruff SA, et al. Eosinophilic esophagitis: epithelial mesenchymal transition contributes to esophageal remodeling and reverses with treatment. *J Allergy Clin Immunol* 2012;129(5):1387.e7-1396.e7.
 44. Hruz P, Straumann A, Bussmann C, et al. Escalating incidence of eosinophilic esophagitis: a 20-year prospective, population-based study in Olten County, Switzerland. *J Allergy Clin Immunol* 2011;128(6):1349.e5-1350.e5.
 45. Ronkainen J, Talley NJ, Aro P, et al. Prevalence of oesophageal eosinophils and eosinophilic esophagitis in adults: the population-based Kalixanda study. *Gut* 2007;56:615-20.
 46. Dellon ES, Jensen ET, Martin CF, Shaheen NJ, Kappelman MD. Prevalence of eosinophilic esophagitis in the United States. *Clin Gastroenterol Hepatol* 2014;12(4):589.e1-596.e1.
 47. Ishimura N, Shimura S, Jiao D, et al. Clinical features of eosinophilic esophagitis: differences between Asian and Western populations. *J Gastroenterol Hepatol* 2015;30:Suppl 1:71-7.
 48. Desai TK, Stecevic V, Chang CH, Goldstein NS, Badizadegan K, Furuta GT. Association of eosinophilic inflammation with esophageal food impaction in adults. *Gastrointest Endosc* 2005;61:795-801.
 49. Aceves SS. Food allergy testing in eosinophilic esophagitis: what the gastroenterologist needs to know. *Clin Gastroenterol Hepatol* 2014;12:1216-23.
 50. Straumann A, Aceves SS, Blanchard C, et al. Pediatric and adult eosinophilic esophagitis: similarities and differences. *Allergy* 2012;67:477-90.
 51. Schoepfer AM, Safroneeva E, Bussmann C, et al. Delay in diagnosis of eosinophilic esophagitis increases risk for stricture formation in a time-dependent manner. *Gastroenterology* 2013;145(6):1230.e1-1236.e2.
 52. Hirano I, Moy N, Heckman MG,

- Thomas CS, Gonsalves N, Achem SR. Endoscopic assessment of the oesophageal features of eosinophilic oesophagitis: validation of a novel classification and grading system. *Gut* 2013;62:489-95.
53. Dellon ES, Gibbs WB, Fritchie KJ, et al. Clinical, endoscopic, and histologic findings distinguish eosinophilic esophagitis from gastroesophageal reflux disease. *Clin Gastroenterol Hepatol* 2009;7:1305-13.
54. Moawad FJ, Robinson CL, Veerappan GR, Summers TA, Maydonovitch CL, Wong RK. The tug sign: an endoscopic feature of eosinophilic esophagitis. *Am J Gastroenterol* 2013;108:1938-9.
55. Gentile N, Katzka D, Ravi K, et al. Oesophageal narrowing is common and frequently under-appreciated at endoscopy in patients with oesophageal eosinophilia. *Aliment Pharmacol Ther* 2014;40:1333-40.
56. Menard-Katcher C, Swerdlow MP, Mehta P, Furuta GT, Fenton LZ. Contribution of esophagram to the evaluation of complicated pediatric eosinophilic esophagitis. *J Pediatr Gastroenterol Nutr* 2015 May 20 (Epub ahead of print).
57. Dellon ES, Speck O, Woodward K, et al. Distribution and variability of esophageal eosinophilia in patients undergoing upper endoscopy. *Mod Pathol* 2015;28:383-90.
58. Ravi K, Talley NJ, Smyrk TC, et al. Low grade esophageal eosinophilia in adults: an unrecognized part of the spectrum of eosinophilic esophagitis? *Dig Dis Sci* 2011;56:1981-6.
59. Collins MH. Histopathologic features of eosinophilic esophagitis and eosinophilic gastrointestinal diseases. *Gastroenterol Clin North Am* 2014;43:257-68.
60. Sridhara S, Ravi K, Smyrk TC, et al. Increased numbers of eosinophils, rather than only etiology, predict histologic changes in patients with esophageal eosinophilia. *Clin Gastroenterol Hepatol* 2012;10:735-41.
61. Abonia JP, Wen T, Stucke EM, et al. High prevalence of eosinophilic esophagitis in patients with inherited connective tissue disorders. *J Allergy Clin Immunol* 2013;132:378-86.
62. Jensen ET, Eluri S, Lebowhl B, Genta RM, Dellon ES. Increased risk of eosinophilic esophagitis in patients with active celiac disease on biopsy: results from a national pathology database. *Clin Gastroenterol Hepatol* 2015;13:1426-31.
63. Mulder DJ, Hookey LC, Hurlbut DJ, Justinich CJ. Impact of Crohn disease on eosinophilic esophagitis: evidence for an altered T(H)1-T(H)2 immune response. *J Pediatr Gastroenterol Nutr* 2011;53:213-5.
64. Alexander JA, Jung KW, Arora AS, et al. Swallowed fluticasone improves histologic but not symptomatic response of adults with eosinophilic esophagitis. *Clin Gastroenterol Hepatol* 2012;10(7):742.e1-749.e1.
65. Straumann A. Treatment of eosinophilic esophagitis: diet, drugs, or dilation? *Gastroenterology* 2012;142:1409-11.
66. Spergel JM. Eosinophilic esophagitis in adults and children: evidence for a food allergy component in many patients. *Curr Opin Allergy Clin Immunol* 2007;7:274-8.
67. Peterson KA, Byrne KR, Vinson LA, et al. Elemental diet induces histologic response in adult eosinophilic esophagitis. *Am J Gastroenterol* 2013;108:759-66.
68. Arias A, González-Cervera J, Tenias JM, Lucendo AJ. Efficacy of dietary interventions for inducing histologic remission in patients with eosinophilic esophagitis: a systematic review and meta-analysis. *Gastroenterology* 2014;146:1639-48.
69. Kagalwalla AF, Sentongo TA, Ritz S, et al. Effect of six-food elimination diet on clinical and histologic outcomes in eosinophilic esophagitis. *Clin Gastroenterol Hepatol* 2006;4:1097-102.
70. Molina-Infante J, Arias A, Barrio J, Rodríguez-Sánchez J, Sanchez-Cazalilla M, Lucendo AJ. Four-food group elimination diet for adult eosinophilic esophagitis: a prospective multicenter study. *J Allergy Clin Immunol* 2014;134(5):1093.e1-1099.e1.
71. Lucendo AJ, Arias A, González-Cervera J, et al. Empiric 6-food elimination diet induced and maintained prolonged remission in patients with adult eosinophilic esophagitis: a prospective study on the food cause of the disease. *J Allergy Clin Immunol* 2013;131:797-804.
72. Katzka DA, Geno DM, Ravi A, et al. Accuracy, safety, and tolerability of tissue collection by Cytosponge vs endoscopy for evaluation of eosinophilic esophagitis. *Clin Gastroenterol Hepatol* 2015;13(1):77.e2-83.e2.
73. Cheng E, Zhang X, Huo X, et al. Omeprazole blocks eotaxin-3 expression by oesophageal squamous cells from patients with eosinophilic oesophagitis and GORD. *Gut* 2013;62:824-32.
74. Dellon ES, Speck O, Woodward K, et al. Markers of eosinophilic inflammation for diagnosis of eosinophilic esophagitis and proton pump inhibitor-responsive esophageal eosinophilia: a prospective study. *Clin Gastroenterol Hepatol* 2014;12:2015-22.
75. Molina-Infante J, Rivas MD, Hernandez-Alonso M, et al. Proton pump inhibitor-responsive oesophageal eosinophilia correlates with downregulation of eotaxin-3 and Th2 cytokines overexpression. *Aliment Pharmacol Ther* 2014;40:955-65.
76. Wen T, Dellon ES, Moawad FJ, et al. Transcriptome analysis of proton pump inhibitor-responsive esophageal eosinophilia reveals proton pump inhibitor-reversible allergic inflammation. *J Allergy Clin Immunol* 2015;135:187-97.
77. Aceves SS, Newbury RO, Chen D, et al. Resolution of remodeling in eosinophilic esophagitis correlates with epithelial response to topical corticosteroids. *Allergy* 2010;65:109-16.
78. Blanchard C, Mingler MK, Vicario M, et al. IL-13 involvement in eosinophilic esophagitis: transcriptome analysis and reversibility with glucocorticoids. *J Allergy Clin Immunol* 2007;120:1292-300.
79. Butz BK, Wen T, Gleich GJ, et al. Efficacy, dose reduction, and resistance to high-dose fluticasone in patients with eosinophilic esophagitis. *Gastroenterology* 2014;147(2):324.e5-333.e5.
80. Schaefer ET, Fitzgerald JF, Molleston JP, et al. Comparison of oral prednisone and topical fluticasone in the treatment of eosinophilic esophagitis: a randomized trial in children. *Clin Gastroenterol Hepatol* 2008;6:165-73.
81. Gupta SK, Vitanzo JM, Collins MH. Efficacy and safety of oral budesonide suspension in pediatric patients with eosinophilic esophagitis. *Clin Gastroenterol Hepatol* 2015;13(1):66.e3-76.e3.
82. Straumann A, Conus S, Degen L, et al. Budesonide is effective in adolescent and adult patients with active eosinophilic esophagitis. *Gastroenterology* 2010;139(5):1526.e1-1537.e1.
83. Kuchen T, Straumann A, Safroneeva E, et al. Swallowed topical corticosteroids reduce the risk for long-lasting bolus impactions in eosinophilic esophagitis. *Allergy* 2014;69:1248-54.
84. Dellon ES, Sheikh A, Speck O, et al. Viscous topical is more effective than nebulized steroid therapy for patients with eosinophilic esophagitis. *Gastroenterology* 2012;143(2):321.e1-324.e1.
85. Hübner M, Hochhaus G, Derendorf H. Comparative pharmacology, bioavailability, pharmacokinetics, and pharmacodynamics of inhaled glucocorticosteroids. *Immunol Allergy Clin North Am* 2005;25:469-88.
86. Moawad FJ, Cheatham JG, DeZee KJ. Meta-analysis: the safety and efficacy of dilation in eosinophilic oesophagitis. *Aliment Pharmacol Ther* 2013;38:713-20.
87. Lipka S, Keshishian J, Boyce HW, Estores D, Richter JE. The natural history of steroid-naïve eosinophilic esophagitis in adults treated with endoscopic dilation and proton pump inhibitor therapy over a mean duration of nearly 14 years. *Gastrointest Endosc* 2014;80:592-8.
88. van Rhijn BD, Smout AJPM, Brede-noord AJ. Disease duration determines health-related quality of life in adult eosinophilic esophagitis patients. *Neurogastroenterol Motil* 2014;26:772-8.
89. Straumann A, Conus S, Degen L, et al. Long-term budesonide maintenance treatment is partially effective for patients with eosinophilic esophagitis. *Clin Gastroenterol Hepatol* 2011;9(5):400.e1-409.e1.
90. Wen T, Stucke EM, Grotjan TM, et al. Molecular diagnosis of eosinophilic esophagitis by gene expression profiling. *Gastroenterology* 2013;145:1289-99.

Copyright © 2015 Massachusetts Medical Society.